PSG Medi Pulse

News ■ Medical ■ Surgical ■ General

Patron

Director : Dr.J.S.Bhuvaneswaran

Editorial Board:

Dr.Vimal Kumar Govindan
Dr.Pavai Ganesan
Dr.T.M.Subba Rao
Dr.Muruganand Mylswamy
Dr.Varunn

PSG HOSPITALS

Peelamedu, Coimbatore -641004

psgmedipulse@gmail.com

www.psghospitals.com

+91 82200 13330

For Emergency : +91 74491 08108

A life full of achievements
Your legacy will live for ever

Shraddhanjali

Dr.S.RAMALINGAM

30.09.1960 - 30.07.2021

The longest serving and beloved Dean of
PSG Institute of Medical Sciences & Research, Coimbatore, Tamilnadu

Na jayate mriyate va kadacin nayam bhutva bhavita va
na bhuyah ajo nityah sasvato
'yam purano na hanyate hanyamane sarire
(For the soul there is never birth nor death. Nor, having once been,
does he ever cease to be. He is unborn, eternal,
ever-existing, undying and primeval).

PSG INSTITUTE OF
MEDICAL SCIENCES & RESEARCH
PSG HOSPITALS
Coimbatore

"Dr. Ramalingam Is a pole star for us. Although he has left us physically he shall continue to guide us. We miss him"

Dr. J S Bhuvaneswaran
Director
PSG SSH

"Dr.S.Ramalingam A tall leader, wonderful teacher, a pragmatist, connoisseur of research, and a philanthropist. Your life was an ode to the students, alumni, faculty, and staff of PSGIMSR and PSG Hospitals."

Dr. T.M. Subba Rao
Principal
PSG Institute of Sciences & Research

Message

குறள் :

வையத்துள் வாழ்வாங்கு வாழ்பவன் வான்உறையும்
தெய்வத்துள் வைக்கப் படும்.

சாலமன் பாப்பையா :

உலகத்தில் வாழவேண்டிய அறநெறியில் நின்று வாழ்கிறவன், வானுலகத்தில் உள்ள தெய்வ முறையில் வைத்து மதிக்கப்படுவான்.

Medical

PSG VAIDYA

PSG in partnership with Coimbatore Cancer Foundation is providing home-based Palliative Care services to those suffering from chronic diseases within city limits. Initially to start up with the focus will be on oncology, respiratory and geriatric patients. Other specialties will be added as we progress.

Pain and palliative medicine at PSG hospital provides pain relief and comfort care to patients suffering from life-threatening or life-limiting medical conditions. We aim to improve the quality of life irrespective of the nature of the disease, be it cancerous, non-cancerous disease (curable, incurable, or end of life). A multidisciplinary team approach with patients and family members at the center is our priority. Counseling the patient and the family members facing life-threatening illness plays an important and integral part of our comfort care.

Services that we provide:

Home-based care

- Vitals & General check-up
- Hypertension Management
- Diabetic Management
- Physiotherapy Mobilization
- Wound Dressing
- Sponge Bath
- Ryles Tube Insertion
- Urinary Catheterization
- Ostomy Care (Tracheostomy / Colostomy)
- Blood Sample Collection
- Patient-Focused Care

Counseling

- General Counselling
- Nutritional Counselling
- End of Life Care Training for Family & Caregivers
- Bereavement Support

We follow a holistic model of care, managing symptoms, and pain while also addressing the emotional and spiritual well-being of patients and their families at their homes.

Medical

PSGH never compromises the healthcare of people even the poor. It is proved once again. Evidence based case report from the Dept. of ENT.

Dr. S Palaninathan, Dr S.Sathiyabama, Dr. Kishore Kumar P

42 years male, A.Tamilselvan ,O21001562 came to EMD on 11-1-21 for the c/o swelling of left eye and face,2-3 days duration.

Also had tooth ache.H/O fever 2 days back.
Known case of type 2 diabetes on drugs

O/E General condition

He was toxic, pain score was 4. Left Eye swelling ,left diffuse cheek swelling and left side upper row tooth numbness with gum inflammation.

Diagnostic nasal endoscopy: deviated nasal septum to left,Mucopus filled in left Middle meatus.Right side nasal cavity looks normal.

Ophthal opinion:

Retro choroidal coloboma ,media hazy imc/pscr

Provisional diagnosis: Left orbital cellulitis secondary to invasive fungal sinusitis(Mucor)

Reports : glycosilated hemoglobin 14.8%

Fasting blood sugar 461mg/dl

Magnesium-1.45meq/l

Covid negative

CT Scan paranasal sinuses:left maxillary sinus mucosal thickening.widening of maxillary infundibulum.

Medical

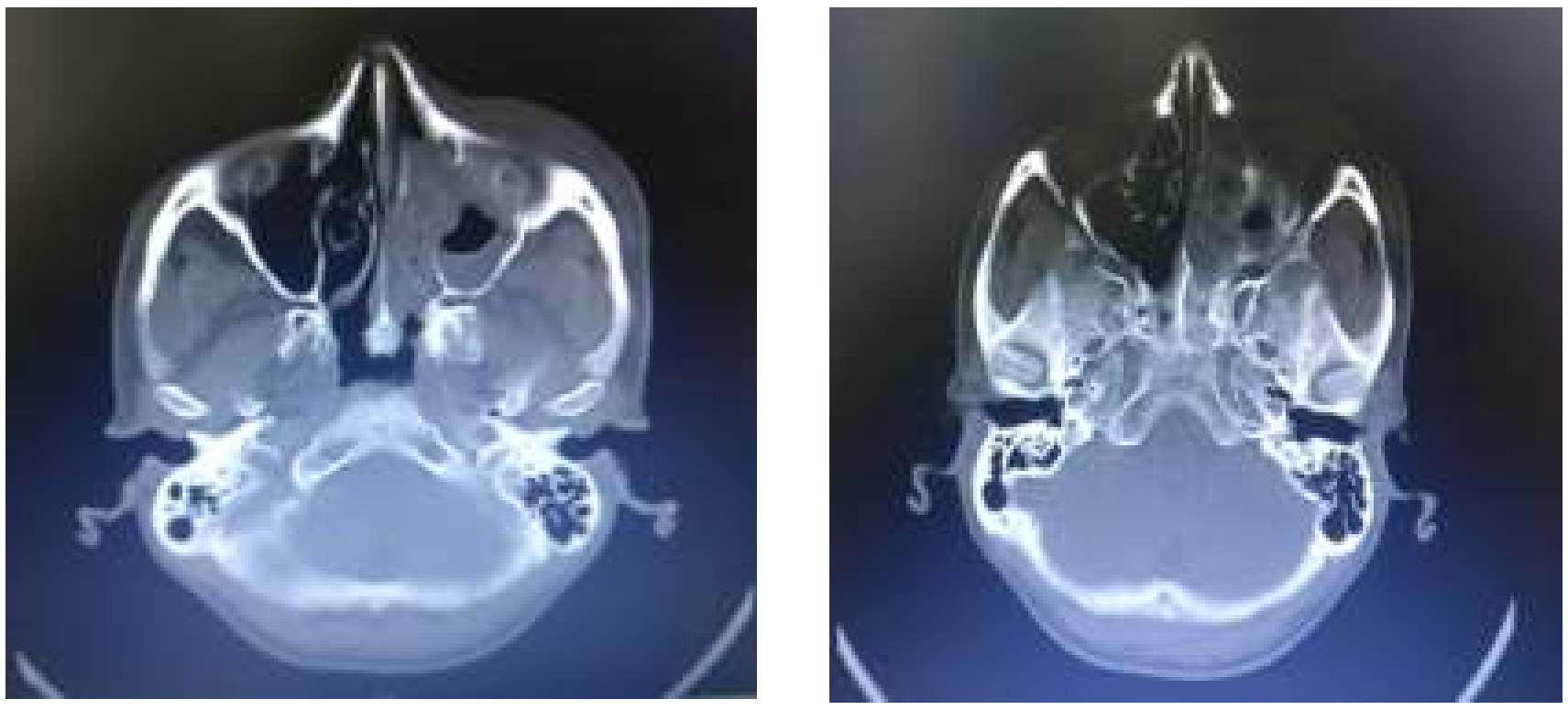

Fig1.CT findings

On 12/1/21 Surgical management : FESS DEBRIDEMENT: Left middle meatal antrostomy with debridment of maxillary sinus cavity done on 13-1-2021.whitish slough like material removed.Tissue material sent for HPE.

HISTO-PATHOLOGY

Lab Ref No :	21H000224	Page :	1 of 1
Sample Coll on :	16/01/21 08:46	Reported on :	19/01/21 12:17
Name :	TAMILSELVAN A	Reg .No :	I21001004
Age :	42 Yrs / M	Dept/Unit :	ENT / CA2F/

Test Name

SMALL BIOPSY(NON-SKIN)

CLINICAL DIAGNOSIS

Left fungal sinusitis

SPECIMEN

Left sided endoscopic debridement

GROSS FEATURES

Grossed by : Drs Nandhini Bala / Ruveka V

Received multiple fragments of pale to dark brown material on aggregate mea. 1.2cm across. 1 block. All embedded.

MICROSCOPIC APPEARANCE

Sections show fragments of mucosa lined by respiratory type of epithelium exhibiting squamous metaplasia. The subepithelium shows edema, seromucinous glands and dense mixed inflammatory cell infiltrate consisting of lymphocytes and plasma cells admixed with many neutrophils, eosinophils and foreign body type of multinucleated giant cells. Also seen are extensive areas of haemorrhage, necrosis and multiple broad aseptate hyphae with wide angle branching morphologically resembling mucormycosis. Tissue and angioinvasion are also noted.

PAS and GMS stains highlights the fungal organisms.

DIAGNOSIS

LEFT SIDED ENDOSCOPIC DEBRIDEMENT : INVASIVE FUNGAL SINUSITIS WITH FUNGAL ORGANISM, MORPHOLOGICALLY RESEMBLING MUCORMYCOSIS.

Fig2. Histopathology Report:

Post operative review done . Diagnostic nasal endoscopy showed edematous congested mucosa in maxillarysinus. Hard palate discoloured in leftside. Nasal toileting done and patient refered to Medicine opd for Antifungal drugs.

Patient attended Medicine OPD for antifungal treatment. Prescribed CRESEMBA injection followed by tablets. Due to high cost of antifungal drugs, he could not complete antifungal treatment.

He then reported to ENT OPD on February 1st 2021 with very severe head ache and eye pain.
On that day we examined him Findings.

1. DNE showed left maxillary ostium filled with whitish debris and
2. Hard palate erosion filled with white slough.

Fig 3

Plan: Alternative days cleaning of maxillary and hard palate with conventional amphotericin B (cost Rs.325)

After 5-6 sitting all his complaints (facial pain,Head ache,facial swelling &eye pain) reduced .palate wound healed well.

Fig 4

Carry home message:

There is a role for proper debridement followed by cleaning and local application of amphotericin B in invasive Fungal Rhinosinusitis.

This is one of the example of many cases treated successfully by our ENT department.

Medical

வாழ்வை காக்கும் பி.எஸ்.ஜியின் 'வஜ்ரம்'

கோவிட் புனர்வாழ்வு திட்டத்தில் ஒரே மாதிரியான பயிற்சிகள் அனைவருக்கும் கற்றுத் தருவதில்லை. நோயாளிகளின் உடல்திறன் மற்றும் அவருக்கு இருக்கும் பிரச்சனைகளை பொறுத்து ஒவ்வொருவருக்கும் கற்றுத்தரும் பயிற்சிகள் மாறுபடும்.

- டாக்டர் வி.ராமமூர்த்தி, தலைவர், புனர்வாழ்வு மருத்துவத்துறை, பி.எஸ்.ஜி மருத்துவமனை

யோகா ஓர் வாழ்க்கை முறை!

பெற்றோர்கள் தங்கள் குழந்தைகளின் வாழ்க்கையில் யோகாவை ஒரு அங்கமாக புகுத்துவதால் குழந்தைகளிடையே வளைந்து கொடுக்கக்கூடிய திறன், வலிமை, சகிப்புத்தன்மை, கவனம் மற்றும் நினைவாற்றல் மேம்படுதல், தன்னம்பிக்கை, பிறருடன் நல்ல நட்புபாராட்டுதல், நம்பிக்கையான பார்வையை ஊக்குவித்தல் போன்ற பல நன்மைகளை அறுவடை செய்திட முடியும்.