



PSG Medi Pulse

■ News ■ Medical ■ Surgical ■ General

Patrons

Dean : Dr.S.Ramalingam
Director : Dr.J.S.Bhuvaneshwaran

Editorial Board:

Dr.Vimal Kumar Govindan
Dr.Pavai Ganesan
Dr.T.M.Subba Rao
Dr.Muruganand Mylswamy
Dr.Deepa Lakshmi



PSG HOSPITALS

Peelamedu, Coimbatore -641004

✉ psgmedipulse@gmail.com

🌐 www.psghospitals.com

☎ +91 82200 13330

For Emergency : +91 74491 08108

Welcome to our New Doctors



Dr. MAJOR K KAMALANATHAN
MBBS, MS General Surgery
D.Ortho, DNB Ortho, MNAMS (Ortho)
Department of Orthopaedics



Dr. THIRUMAL
MBBS, MS Paediatric and
DM Gastro, Department of
Gastroenterology



Dr. PANDIAN BASKAR RAO
MD., RT., DM.,
Department of Oncology

Message

குறள் :

உறுப்பொத்தல் மக்களொப்பு அன்றால் வெறுத்தக்க
பண்பொத்தல் ஒப்பதாம் ஒப்பு.

மு. வரதராசன் விளக்கம் :

உடம்பால் ஒத்திருத்தல் மக்களோடு ஒப்புமை அன்று,
பொருந்தத்தக்கப் பண்பால் ஒத்திருத்தலை
கொள்ளத்தக்க ஒப்புமையாகும்.

Medical

DEPARTMENT OF CARDIO THORACIC AND
VASCULAR SURGERY & INTERVENTIONAL RADIOLOGY

A RARE CASE OF DELAYED RADIATION INDUCED VASCULOPATHY - A Case Report

Dr. Murugesan. P. R, Dr. Elango, Dr. Murugan. M.S,
Dr. Basheer Ahmed Showkath Ali, Dr. Sashi Bindhu Kokkireni

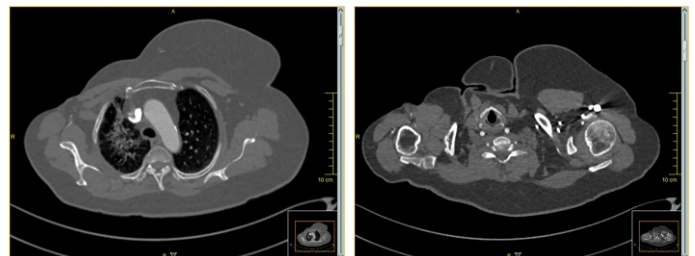
Introduction:

Radiation induced arteritis is a rare but a well known complication of radiotherapy. Radiation is known to cause inflammation, intimal thickening and fibrosis in the blood vessels along radiation field. They mimic atherosclerosis, however location within the radiation field and absence of atherosclerosis elsewhere suggest possibility of radiation induced arteritis. The most commonly affected vascular beds due to radiation include cervical and intracranial vessels (Oropharyngeal), iliac vessels (Uterine cervical cancer) and visceral arteries(lymphoma and bowel malignancies). Here we report the presentation and endovascular management of a patient who developed radiation induced arteritis after 19 years.

Case History:

A 60 years women came with complaints of claudication pain in the right arm and was admitted under CTVS for evaluation and management. On Local examination, pulses were not felt in the right upper arm with cold periphery and increased capillary refill time. The patient is a known hypertensive and she underwent Modified Radical Mastectomy 19 years back for carcinoma breast (Stage 3) followed by chemo-radiotherapy. CT Angiogram revealed post operative changes in the right side with fibrosis along the radiation field. The Right subclavian artery was normal, however the distal axillary artery and proximal brachial artery showed a focal occlusion (4 cm) with peri arterial fibrosis and distal reformation. Due to the location of the occlusion in the radiation field, presence of peri arteric fibrosis, and absence of atherosclerosis anywhere else in the body possibility of Radiation induced arteritis was suspected.

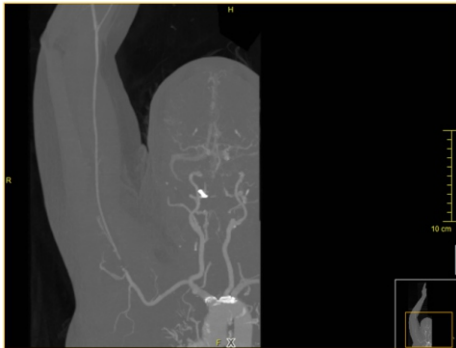The presence of post op fibrotic changes precluded surgical revascularisation. Hence Per cutaneous intervention was planned and the patient underwent Angioplasty. Antegrade approach via femoral access was attempted, but was not successful as we were unable to pass the guide wire through the occluded segment. Retrograde approach via Brachial access was performed subsequently. As the brachial artery was small in caliber and non pulsatile, ultrasound guided puncture was done and the access was preserved using a short sheath under continuous flush to prevent spasm and clot formation (infusion Nimodipine and Heparin)Through this technique (retrograde technique) we were able to pass the guide wire (Guide wire-035 Terumo) across the occlusion. Balloon dilatation and drug eluting balloon angioplasty was performed. Check angiogram revealed good distal flow without any residual stenosis or dissections. Stenting was planned initially, however deferred due to mismatch between proximal and distal landing zones. (proximal 4 mm to distal 2 mm). The patient was started with dual antiplatelet therapy and statins.



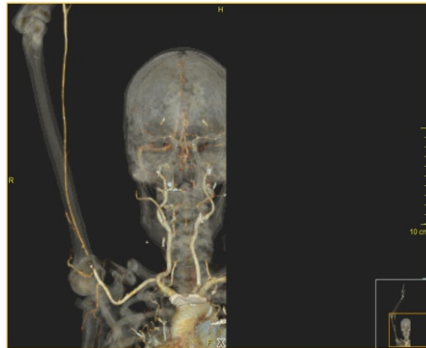CT showing Fibrosis on Right lung and Right Mastectomy

Medical

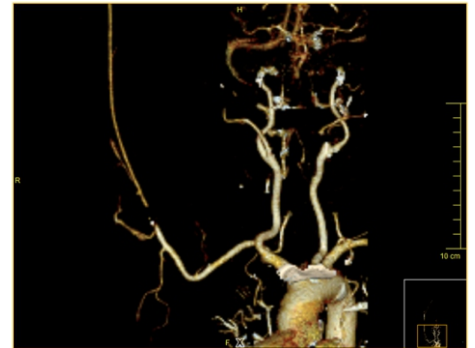
On follow up after 6 months the patient had good radial pulse and was symptom free



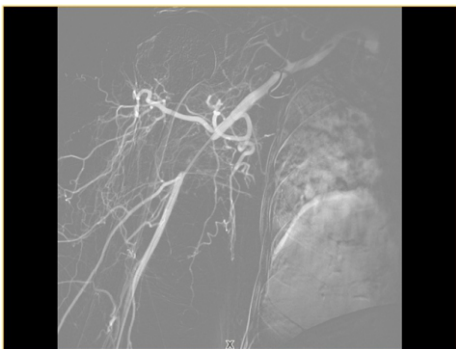
Right side Axillary Artery is not visible



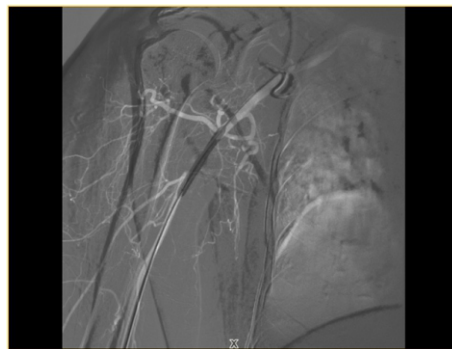
CT Angio showing occlusion of Right Axillary artery



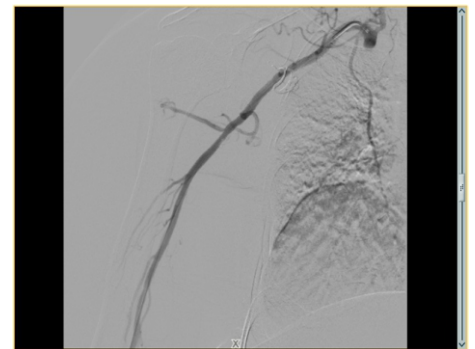
3D image showing cutdown of axillary artery flow



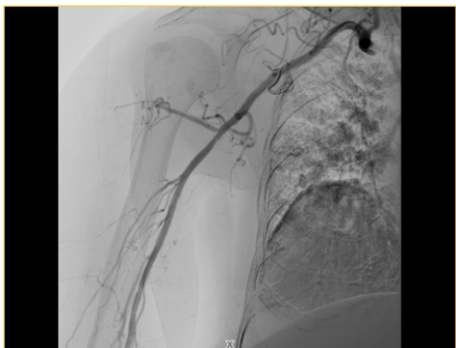
Angiogram showing occluded segment



Balloon dilation of the axillary artery



Flow established during the procedure



Flow established after the procedure

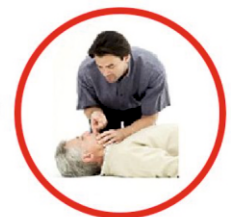Heart Attack

Emergency First Aid

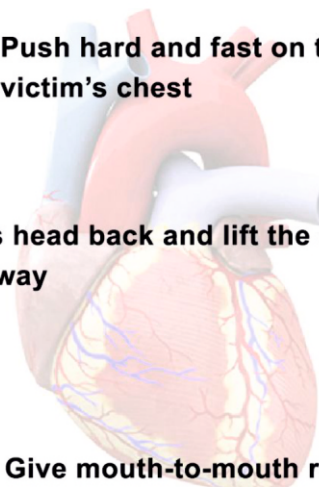


Push hard and fast on the center of the victim's chest

Tilt the victim's head back and lift the chin to open the airway



Give mouth-to-mouth rescue breaths



Medical

DEPARTMENT OF CARDIO THORACIC & VASCULAR SURGERY IATROGENIC ULNAR ARTERY PSEUDOANEURYSM EMERGENCY REPAIR - A CASE REPORT

Dr. Murugesan.P.R , Dr. Murugan.M.S , Dr. Ganesan.C , Soundarya.E
Dr. Sashi Bindhu Kokkereni, Dr. Basheer Ahmed Showkath Ali

INTRODUCTION

This report describes the management of a female patient with a rare vascular emergency of iatrogenic right ulnar artery pseudoaneurysm presented as an expanding hematoma with right forearm compartment syndrome following a PCI (percutaneous coronary intervention) done to place stent in the LAD artery through right transulnar approach (Radial non-dominant).

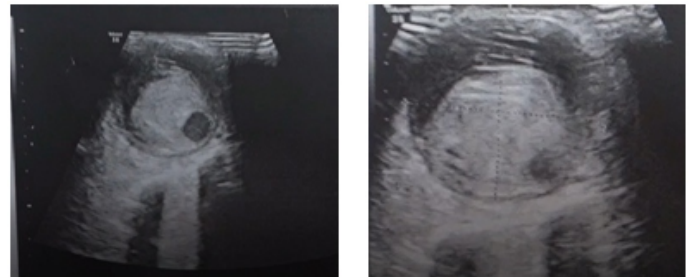Iatrogenic pseudoaneurysm forms when an arterial puncture site following any medical intervention fails to seal, allowing arterial blood to jet into the surrounding tissues and form a hematoma. These lesions lack a fibrous wall and are contained by a surrounding wall of hematoma and the overlying soft tissues and if left untreated they can cause compartment syndrome and later paralysis of limbs due to nerve compression, therefore emergency intervention is required.

CASE PRESENTATION

A moderately built 71 years old female, a known hypothyroid on regular medications was referred to the cardiovascular surgeons with a well defined mass on the flexor aspect of the right forearm associated with severe localised pain, insidious in onset and progressive in nature following a week after the PCI procedure done through right transulnar approach for stent placement in the LAD in some other hospital. The mass was associated with tenderness and weakness of right forearm and hand.

On doppler examination of the right ulnar artery distal to the mass, no blood flow detected. General examination was unremarkable.

USG of right forearm revealed a pseudoaneurysm with thrombus formation noted arising from right ulnar artery in forearm about 5 cm from the wrist measuring about 5.5x3.6x3.2 cm. Maximal diameter of lumen measures 10.1mm with to and fro flow. Low monophasic flow noted in distal ulnar artery. Median nerve, muscles, and tendons appear normal.



As this case required emergency intervention, open surgical repair was done. The surgery was done under supraclavicular block with axillary supplementation. A vertical incision made at right midforearm near the ulnar side and the clot was evacuated. After the clot evacuation, the ulnar artery puncture site was sutured. After hemostasis secured, the incision site was closed with subcuticular suturing.

DISCUSSION

Iatrogenic pseudoaneurysms typically occur following percutaneous arterial interventions. Before doing any arterial intervention in the upper arm, clinical tests like Allen's and reverse Allen's can be done. In Allen's test, the radial artery occlusion is maintained with digital pressure to assess the palmar inflow through ulnar artery. In reverse Allen's test, the ulnar artery occlusion is maintained with digital pressure to assess the palmar inflow through radial artery. Upper arm PCI is usually done through radial artery. If radial artery access is unsuccessful, PCI is done through ulnar

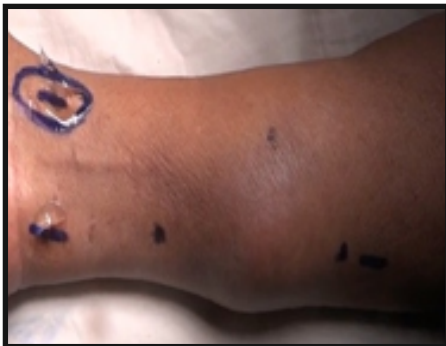artery. Access to the ulnar artery is generally difficult compared to radial artery because it is less pulsatile because of its deeper location. In case PCI is done through radial artery and is unsuccessful, ipsilateral ulnar artery access is not recommended on the same day because of potential spasm incited in the radial artery that could result in hand ischemia if the ulnar artery becomes occluded or goes into spasm. Factors which increases the risk of iatrogenic pseudoaneurysm after ulnar artery catheterization is due to procedural and patient factors. Procedural factors are inadvertent catheterization, interventional rather than diagnostic procedures, inadequate compression following removal of sheath. Patient factors are obesity and patients on anti-coagulant medications post procedure.

Iatrogenic pseudoaneurysm usually presents with pain, swelling in the affected region along with

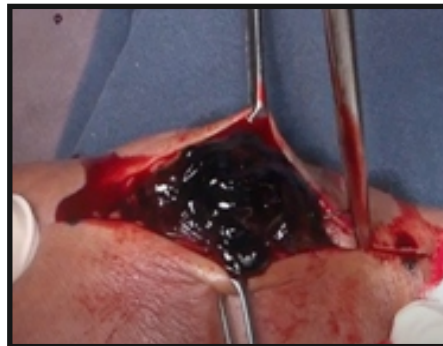palpable mass (hematoma) which may be pulsatile with a thrill or bruit. Angiography remains the gold standard in detecting vascular injury, several articles outline that the use of USG, multidetector CTA and magnetic resonance angiography specifically are all effective tool for establishing the diagnosis.

The treatment options available for iatrogenic pseudoaneurysms are open surgical repair (OSR), USG guided compression (UGC), percutaneous ultrasound guided thrombin injection (UGTI). OSR (open surgical repair) is considered to be the gold standard treatment for iatrogenic pseudoaneurysm as the arterial defect is repaired definitively. Main steps of OSR is evacuating the aneurysmal sac and repairing the defect in the arterial wall either by primary or patch closure. Main complications of OSR include blood loss and surgical site infection.

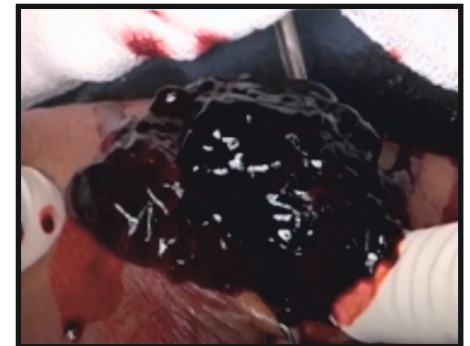
OPEN SURGICAL REPAIR



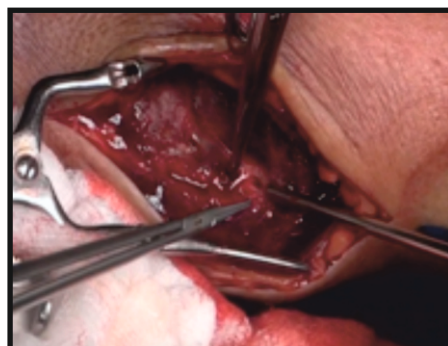
Pre operative picture : Well localised mass on the right forearm, flexor aspect, 5cm



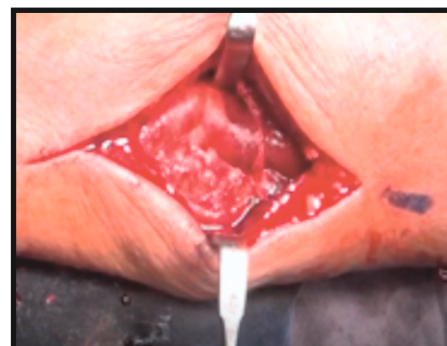Step 1 : A vertical Incision Made



Step 2 : Evacuation of Clot



Step 4 : Ulnar artery puncture site sutured



Step 5 : Haemostasis achieved

General



Sanjaya
Consult Doctor Online



Mithra
Lab on wheels
8220013330



Kavacha
Exclusive Vaccination Center
8220099352



Sanjeevani
Pharmacy at doorstep
8220333747

PSG HOSPITALS

Download
PSG HOSPITALS
PATIENT APP

Peelamedu, Coimbatore - 641 004. Phone : +91 422 2570170 / 4345353
Email : psghospitals@psgimsr.ac.in || Web : www.psghospitals.com
For Emergency 7449 108 108 || Customer Care 97896 80666 || Appointment 82200 13330 || Helpline 822 001 3330